

„Differential Accuracy Analysis“

Note:

Pages 1-4 are an english translation of an article published in german. (Unterbrink G. Differenzierende Analyse der erforderlichen Genauigkeit bei laborgefertigten Restaurationen. Phillip Journal 1997; 11-12: 386-8)

Following this are comments and additional literature references concerning this theme.

Introduction

One often hears two extremes in relation to the required accuracy of indirect adhesive restorations:

- They must fit perfectly, just like gold inlays.
- Excellent fit is not required, because adhesion and composite resin cements will compensate for inaccuracy.

This always reminds me of the tautology „absolute statements are always wrong“. Indeed, both statements are incorrect!

The preparations are different, and the restorative and cementation materials have totally different mechanical characteristics, and the cementation techniques are different. What we need is to analyse the accuracy requirement in relation to the materials and techniques.

It is interesting to compare the accuracy obtained in in-vitro investigations with the accuracy reported in clinical trials. In laboratory studies, primary gap widths of approximately 50 μm are generally obtained. Clinical investigations, however, rarely report values under 100 μm (1-3). In addition to the improved control of variables, laboratory studies frequently utilize a simplified geometry. All of the materials used in the fabrication chain (impression, model, investment, restorative material) show dimensional variation; and therefore the models in the laboratory are never precisely the same as the patient's tooth.

Composite cements are also generally described as the „weak link“ in indirect adhesive restorations. Three factors are emphasized; the shrinkage and potential gap formation, the difficulty in controlling excess cement, and the wear resistance. These factors are also interrelated.

Polymerization Shrinkage

The effects of polymerization shrinkage are determined by the specific clinical situation, but we can describe two theoretical extremes. With „restricted“ shrinkage, movement of the objects is eliminated. In this situation, accuracy is critical; and the „best“ fit will generally provide the best result (4, 5). Unrestricted shrinkage implies that at least one of the objects can move. Studies reveal an interesting fact; the best result is not obtained with the thinnest cement layer, but rather with resin cement thicknesses of about 100 to 200 μm (6, 7).

Naturally, we are rarely dealing with these extremes clinically. The cementation of an adhesive post is certainly restricted and a crown comes very close to the restricted situation, and in lab studies the inner surface is almost always characterized by partial gap formation. (The theoretical maximum cement thickness can be calculated mathematically, provided certain assumptions are made concerning bond strengths and modulus development. With

ceramic restorations and a bond to dentin of 20 Mpa, the maximum "acceptable" cement layer thickness is about 100 µm.) With veneers or flat onlay preparations, we have a less restricted situation, and the shrinkage can „pull“ the restoration toward the tooth surface. The low failure rates with these types of restorations can perhaps be explained on this basis.

Class 2 Inlays (and Onlays)

In the following, I would like to look at the situation with Class 2 inlays. Cusp deformation has been documented in many studies (9, 10). While it is not possible to define a „magic number“ where problems may occur, it appears that cusp deformation of 20-30 µm does not lead to any clinical difficulties (11). The vertical walls of a Class 2 preparation can therefore be defined as having a tendency toward unrestricted shrinkage due to cusp compliance. A cement thickness of 200 µm at both walls, assuming a linear shrinkage of 5%, would cause a cusp deformation of approximately 20 µm. Horizontal walls, which includes the critical gingival margin, are much closer to the restricted situation; the best possible accuracy is desired in these locations.

If perfect accuracy at all margins is attempted, the usual result is an inlay which does not seat fully. The result is increased cement thickness at the gingival margin and the occlusal floor. Gaps at the gingival margin will lead to temperature sensitivity and an increased risk of secondary caries. Gaps at the occlusal floor produce the classic „inlay sensitivity“ upon occlusal loading. Additionally, the removal of excess composite cement interproximally must be done prior to polymerization. There are a variety of techniques recommended, which all have one fact in common. Primary gap widths of over 100 µm at the gingival margins will almost always lead to a poor result.

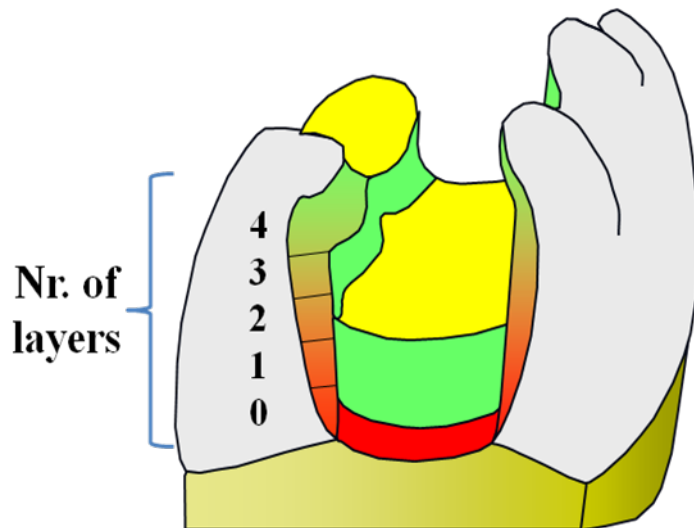
Fact: our clinical problems are nearly always related to horizontally oriented surfaces!

Technique Modification

The first step toward solving this problem is performed in the laboratory. Die spacer should be applied on all vertical walls to (over) the margins, i.e. intentionally creating a wider gap at occlusal and axial margins. The thickness of the die spacer depends on the geometry of the preparation, we use up to 5 layers of a die spacer with a (claimed) thickness of 20 µm. Naturally the cusps do not bend at the corner of the proximal box, so use increasing thickness toward the occlusal (see illustration). The more complex the preparation, the more layers of die spacer will be required. I use the basic rule "More curves need thicker layers: except in the fashion industry." The inlay should seat with no friction at all.

Compromising the accuracy on vertical walls, including the margins, is the only method which will guarantee the best possible accuracy at the horizontal surfaces. I additionally request the application of one layer of die spacer to the occlusal floor in a thin layer, as well as over all horizontally oriented, „accessible“ buccal and lingual margins.

Do NOT let your laboratory use more than one layer of die spacer on the occlusal floor, nor should any type of block-out material be used. This will increase the risk of sensitivity to occlusal pressure.



Red areas: no spacer

Yellow areas: one layer

Green areas: not critical, up to four or five layers at occlusal margins

Cement Wear

Die-spacing over the occlusal margins will increase cement thickness in these areas, and you may now be thinking "One problem solved and a different problem created". Laboratory results correlating cement width and vertical wear would indicate increased vertical wear with more exposed composite (12). However, I think you will find this correlation only in the laboratory or with short-term clinical studies, but that this difference diminishes or disappears after several years clinically (13-15).

After light-curing, the composite has only achieved a fraction of its final physical properties (16, 17). An important factor is what I call „secondary“ oxygen inhibition, or inhibition of post-cure. The thickness of this layer can reach 0.25 mm (18), and composite cement wear is correlated with the monomer conversion, especially with hybrid materials (19). Post-curing is extremely dependent upon the ambient temperature (20). (Think about the various heat treatments recommended for laboratory composites.) Judicious dry polishing can accelerate the post-cure and limit the effects of secondary inhibition.. The thermal diffusion coefficient of composite and ceramic is low, so pulpal effects from the increased temperature will not occur if common sense is used.

A prerequisite for dry polishing is a small amount of excess, it is impossible to dry polish a „negative“ margin; i.e. a groove. Here we see an interaction with the clinical technique, and I therefore prefer to polymerize all accessible margins with an excess of cement. Finishing these margins precisely at the cementation appointment is not easy, and I don't even try. As long as the occlusion is correct, what damage does excess cement do on the occlusal surface? I have never understood the emphasis on precise finishing of occlusal margins, since fissure sealants are nothing but excess! Who cares? Naturally, these margins may require minor refinishing at a subsequent appointment, but this cannot be avoided with any technique.

Conclusions (Summary of clinical techniques follows literature)

Frequently, adhesive cementation is reduced to the simple substitution of conventional cements with resin-based materials. Unfortunately, the preparation is different, the restorative

materials are brittle, and the classic „fracture technique“ for removal of excess cement does not work well with luting composites. The considerations presented here should not be interpreted as an invitation to poor technique, and of course must be adapted to each combination of impression and model materials. We can continue to demand „perfection“ in relation to accuracy, and dentists in private practice will continue to have problems. By adapting the laboratory methods and the cementation technique to the specific requirements of adhesive dentistry, the majority of these problems can be solved.

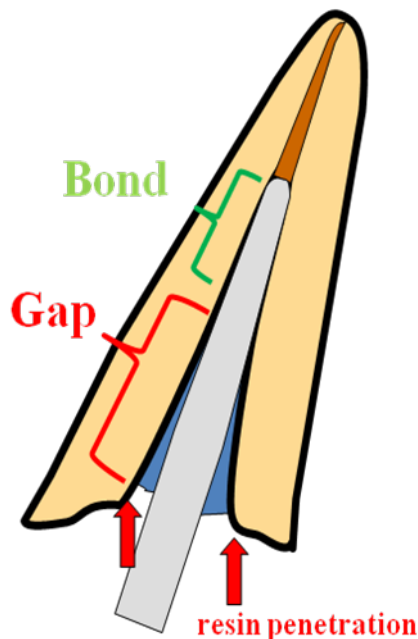
Literature

1. Wöstmann B. Wie genau lassen sich präparierte Zähne am Patient abformen? ZWR 1996; 5: 247-250
2. van Meerbeek B, Inokoshi S, Willems G, Noack MJ, Braim M, Lambrechts P, Roulet JF, Vanherle G. Marginal adaptation of four tooth coloured inlay systems in vivo. J Dent 1992; 20: 18-26
3. Molin M, Karlsson S. The fit of gold and three ceramic inlay systems. A clinical and in vitro study. Acta Odontol Scand 1993; 51: 201-206
4. Sorensen JA, Munksgaard EC. Interfacial gaps of resin cemented ceramic inlays. Eur J Oral Sci 1995; 103: 116-130
5. Gütschow R. Untersuchungen zum Einfluss der Klebschichtstärke auf die plastische Verformung von Industrie- und Dentalklebern. Dtsch Zahnärztl Z 1994; 7: 701-706
6. Chana H, Ibbetson R, Pearson G, Eder A. J Dent Res 1995; 74 (Speical Issue IADR-CED, GB) Abstract 125: 837
7. Sim CPC, Tjan AHL, Liu P. Effect of Cement Film Thickness on Porcelain to Enamel Bonding. J Dent Res 1996 (75) Special Issue; Abstr. 30
8. Lim CC, Ironside JG. The Correlation of Fit and Microleakage in 3 Ceramic Veneer Systems. J Dent Res 1995; 73(3), Div.Abstr 11
9. Pearson GJ, Hegarty SM. Cusp movement in molar teeth using dentin adhesives and composite filling materials. Biomaterials 1987; 8: 473-476
10. Causton BE, Miller B, Sefton J. The deformation of cusps by bonded posterior composite restorations; An in vitro study. Br Dent J 1985; 159: 397-341
11. Lutz F, Krejci I, Barbakow F. Quality and durability of marginal adaptation in bonded composite restorations. Dent Mater 1991; 7: 107-113
12. Kawai K, Isenberg P, Leinfelder K. Effect of gap dimension on composite resin cement wear. Quintessence Int. 1993; 24: 53-58
13. Jäger K, Wirz J, Schmidli F. Porzellaninlays als Amalgamersatz? Schweiz Monatsschr Zahnmed 1990; 100: 1345-1350
14. Hofmann N, Klaiber B, Heners M. Okklusale Randschlussqualität von CEREC-Inlays nach mehrmonatiger Tragedauer. Dtsch Zahnärztl Z 1990; 45: 289-292
15. Mörmann W, Krejci I. Computer-designed inlays after 5 years in situ: clinical performance and scanning electron microscope evaluation. Quintessence Int 1992; 23: 109-115
16. Unterbrink GL, Müssner R. Influence of light intensity on two restorative systems. J Dent 1995; 23: 183-189
17. Leung RL, Adishian SR, Fan PL. (1985) Post-irradiation comparison of composite resins. J.Prosth.Dent;54:645-649
18. Ferracane JL, Mitchem JC, Condon JR, Todd R. Wear and Marginal Breakdown of Composites with Varied Degrees of Cure. J Dent Res 1996; 75 (Special Issue) Abstract 851: 124
19. Lai JH and Johnson AE. (1993) Measuring polymerization shrinkage of photo-activated restorative materials by a water-filled dilatometer. Dent.Mater;9:139-143

FRC post cementation

The most common cause of failure with all post systems is loss of retention. As mentioned above, we are dealing with restricted shrinkage and therefore require the thinnest possible cement (and adhesive) layer.

1. Achieve primary stability at try-in. The post should not wiggle.
2. Thin every adhesive after application with a combination of paper points and dry air. If the adhesive is very thin, there is no requirement to light cure it if used in combination with a dual curing composite cement.
3. Cement is placed with a lentulo spiral or injected directly into the canal (when the injection tip will reach the apical part of the post preparation).
4. Post bonding is advisable, in particular if the post only fits properly in the apical section. Seat the post as usual, remove excess cement from the coronal aspect so that the cement is not covering the opening (see drawing) and light cure for at least 20 seconds (high intensity) or 30 seconds (low intensity). Place a drop of unfilled, solvent free resin, blow away excess, and light cure again. Continue then with the normal build-up of the core or restoration.



Acceleration of cement polymerization from the bonding agent

Some bonding resins dramatically accelerate the setting time of the cement, which can lead to problems when cementing FRC posts. These are generally cements designed for the adhesive cementation of metal-ceramic or zirconium crowns such as Multilink automix or Panavia. Keeping the quantity of adhesive minimal will help avoid problems, but even then, seating the post quickly after applying the cement is necessary. For this reason I prefer to use adhesive-cement combinations with little or no acceleration for this indication.

Summary of clinical and laboratory techniques.

Preparation Appointment

- Keep your preparations „simple“; no little bumps under cusp tips, no long bevels, no palatal chamfer on veneers. (See separate summary of adhesive preparation technique.)
- Block out undercuts before the impression to avoid distortion. (I prefer bonding agent plus flowable composite for small areas, or conventional glass ionomer cement if the preparation is also deep.) If depth is sufficient, cover the dentin of the occlusal floor at the same time.
- External margins should be sharp, rounded margins complicate cement removal.
- Leave the impression in the mouth for the recommended time, this is probably the major factor contributing to distorted impressions and inaccurate models. Remember that some deformation will always occur, and that each step in the laboratory will create additional inaccuracies.

Laboratory

- The technician should die space all vertical surfaces with 1-5 layers TO THE MARGIN! The number of layers depends on the preparation form; the more "complicated" the preparation the more layers you need. You need to discuss this with your technician.
- The technician should NOT use more than one layer of die spacer on the occlusal floor, and NEVER USE ANY BLOCK-OUT!
- One layer of die spacer on „horizontal accessible“ surfaces (onlaid cusps).
- NO die spacer on the gingival proximal margins!
- I find it preferable that the technician does not sandblast gingival margins or the occlusal floor of the restoration. Accuracy here has priority over bond strengths.

Cementation Appointment: “Conventional composite cements”

- Normal try-in. The restoration should seat completely with minimal or no pressure. If it does not, you can play with Fit-Checker, etc.; but it means you need to talk to your technician again!
- Blow the dentin bonding agent as thin as possible, even if different recommendations are in the instructions for use! Light exposure with a thin layer will probably not lead to any polymerization. I still prefer NOT to pre-cure any adhesive.
- Seat with gentle pressure held for a „long time“, at least 15 seconds. The flow of composite cements is different than conventional cements; time is more important than pressure. Try to keep the seating pressure constant until the restoration is fixed, if the restoration moves away from the tooth due to hydraulic pressure and is re-seated, the marginal quality suffers dramatically.
- There are many ways to remove excess cement, and for the most part it is personal preference. Interproximally, wide waxed dental tape with a bit of glycerine works best (I also like Glide tape, the Teflon tape used by plumbers is cheaper and works fine). Superfloss takes too much cement away, thin floss can also go into your margin or catch on even very small edges.
- Should the cement interproximally begin to set prior to removal, using a scaler or curette to fracture it away and polish with finishing strips.

Cementation Appointment: “Conventional composite cements”

Newer composite cements permit removal of resin cement with a conventional technique, i.e. fracturing it off after brief light curing, this works extremely well if the margins of the preparation and restoration are sharp and the cement gap is small. If the margins are rounded, or if the cement thickness is large, this technique is very unpredictable. This is another reason

for concentrating on accuracy at your proximal margins and sharp cavosurface angles. I am not a fan of the self-adhesive cements, their bond strengths are poor, the volumetric shrinkage is similar to other resin based products. Although they will probably provide acceptable clinical results if accuracy is excellent, I see no reason to accept the compromises.

The following are additional references to this subject and related themes which were NOT cited in the original publication. A comment concerning the most important finding is generally added.

Biting sensitivity

Johnson GH, Gordon GE, Bales DJ. Post-operative sensitivity associated with posterior composite and amalgam restorations. *Operative Dent* 1988;13:66-73
Report of 19% incidence of post-operative biting sensitivity with composites clinically. Biting sensitivity is caused by internal gaps on the occlusal floor.

Hirata K, Nakashima M, Sekine I, Mukoyama Y, Kimura K. Dentinal Fluid Movement Associated with Loading of Restorations. *J Dent Res* 1991;70(6):975-978
Well done study. Class 1 cavities in molars with diameter 2 mm and depth of 2.5 mm. Filled with bonded high modulus composite (Clearfil) or amalgam. Occlusal load only 30 kg with 1.5 mm radius steel pin. Very little increase in dentinal fluid movement with amalgam, but significant with composite. In-vivo with dogs (Class 5 in canines with 10 kg load) showed nerve firing with speed of 15 m/s: clearly the A-delta fibers. This corresponds to the type of pain reported by patients.

Note: If a gap formed between the adhesive hybrid layer and the luting composite, the A-delta fibers still fired despite "sealed tubules". The hybrid layer – including tubule obturation with adhesive – is NOT adequate to prevent pressure transfer. (This is particularly interesting in relationship with the recent papers of Franklin Tay concerning extremely hydrophilic bonding agents, which almost universally demonstrate this behavior.)

Die Spacing and Accuracy

One of the key articles to understand "differential accuracy" is the following:

- Dietschi D, Moor L. Evaluation of the Marginal and Internal Adaptation of Different Ceramic and Composite Inlay Systems After an In Vitro Fatigue Test. *J Adhesive Dent* 1999;1:41-56

In this study, there was a clear interrelationship of marginal accuracy vs. internal adaptation: either the margins fit well but internal accuracy was terrible, or naturally in reverse. Gaps on occlusal floor = occlusal load sensitivity. A further finding here was that ED Primer did not perform well: probably shelf life problems.

Although not performed with dentin adhesives and composite cements, this study demonstrates that for complete seating, a space is required.

- Wilson PR, Stankiewicz NR. Effect of cement space and delayed placement on the seating of crowns luted with Vitremer, Fuji Duet and Dyract Cem. *Am J Dent* 1998;11:240-244.

The better the crown fits, the higher the increase in vertical seating discrepancy. You need at least 40 microns of spacer to seat a crown properly with these cements – which incidentally show similar film thicknesses as composite luting agents in laboratory studies. (With 20 microns space, average of 0.1 mm increase in vertical height. This means that if the accuracy

values used in advertising were actually achieved, you would spend 15 minutes adjusting the occlusion and repolishing after every cementation.) Seating delay after mixing was huge problem with Fuji Duet, a delay of more than 60 seconds also a problem with Vitremer.

Audenio G, Bresciano M, Bassi F, Carossa S. In Vitro Evaluation of Fit of Adhesively Luted Ceramic Inlays. *Int J Prosthodont* 1999;12:342-347

Empress overall better than refractory die technique and Celay. This was particularly true on the occlusal floor where it is important to avoid sensitivity.

Adhesives and Composite Cement

Wiskott HWA, Nicholls JJ, Belser UC. The Effect of Tooth Preparation Height and Diameter on the Resistance of Complete Crowns to Fatigue Loading. *Int J Prosthodont* 1997; 10: 207-215.

Retention relates to both height and diameter, as expected. Very different slopes for zinc oxide-eugenol, zinc-phosphate, glass-ionomer, and resin cements. Relationship of retentive strength for the materials approximately 1:2:4:8 respectively, in groups with equivalent height and diameter.

Zuellig-Singer R, Bryant R. Three-year evaluation of computer-machined ceramic inlays: Influence of luting cement. *Quintessence Int* 1998; 29:573-582

Inlays don't have to fit, they only have to fit where they have to fit!

Peter A, Paul SJ, Lüthy H, Schärer P. Film thickness of various dentin bonding agents. *J Oral Rehabilitation* 1997;24:268-293

Not a great paper, but interesting for this comment: "Film thickness of prepolymerized adhesives between 60 and 350 micrometers!" I guess they followed the instructions and dried them gently...

Schärer P and Chen L. Composite-Zemente und Dentinhaftvermittler. *Phillip Journal* 1998;11-12:326-334.

Precuring of adhesive is not recommended.

Frankenberger R, Sindel J, Kraemer N, Petschelt A. Dentin Bond Strength and Marginal Adaptation: Direct Composite Resins vs Ceramic Inlays. *Operative Dent* 1999;24:147-155

Two interesting things:

- Multicomponent bonding agents are better than single component materials.
- Precuring necessary for direct, only minor influence on indirect. (Decent correlation of extrusion method bond strength with marginal adaptation, but only for direct; bond better always with precure, but adaptation was not.) Bonding agents should never be cured in advance.

Berg NG, Derand T. A 5-year evaluation of ceramic inlays (CEREC). *Swed Dent J* 1997; 21:121-1217

Average cement width on occlusal surfaces 373 microns (s.d. 147), depth of „defect“ in cement 111 microns (s.d. 67). Marginal fractures in enamel or at interface to cement were also included as defects, so this number is not just wear. Width to depth showed "minor" correlation with molars, no correlation with premolars (wider cement was not worse, which contradicts Leinfelder's theories based on lab studies. I personally disagree with both the test method and the interpretation of the data from the Alabama lab study). Only 3 failures (fractures) out of 115 inlays despite poor fit.

Fradeani M, Redemagni M. An 11-year clinical evaluation of leucite-reinforced glass-ceramic crowns: A retrospective study. *Quintessence Int* 2002; 33: 503-510
Average years at risk approximately seven. Survival rate of anterior crowns was 98.9%, posterior crowns 84.4%.

Malament KA, Grossman DG. Bonded vs non-bonded Dicor crowns. *J Dent Res* 1992;71:Abstr.321

This study confirms that full ceramics are better if bonded. His failure rate with bonded Empress crowns is significantly lower than the failure rate with „bonded“ InCeram crowns. (Naturally, bonding InCeram should probably be called „non-bonded resin-cemented crowns“.) Other correlation seems to be with modulus of build-up: higher is better. (I still don't understand why people are doing radical crown preps with adhesive full ceramic, but traditions die slowly.)

Microleakage

The following studies are interesting because although some "conservative dentists" criticize resin systems because of microleakage, they are still better than conventional cements, including glass ionomers.

- Kydd WL, Nicholls JJ, Harrington G, Freeman M. Marginal leakage of cast gold crowns with zinc phosphate cement: An in vivo study. *J Prosth Dent* 1996; 75: 9-13 (Also others: Staehle HJ, Ackerman J. *Zahnärztl Welt* 1991; Schmeiser R, Hannig M. *Dtsch Zahnärztl Z* 1994; Andrews JT, Hembree JH. *J Prosth Dent* 1976; showing high microleakage with the "gold standard".)
- White SN, Ingles S, Kipnis V. Influence of marginal opening on microleakage of cemented artificial crowns. *J Prosthet Dent* 1994; 71: 257-264 (Despite poor bonding agents and very thick resin cement layers, the microleakage of the resin-luted crowns was significantly less than zinc-oxyphosphate or glass ionomer.)
- Doruff M, Halvorson R, Keck S. Crown microleakage of various permanent cement products. *J Dent Res* 1995; 72 (special issue): 243, Abstr. 1852 (Zinc-oxyphosphate was the worst, the glass-ionomer and carboxylates in a middle range, with Superbond and Panavia 21 easily the best.)
- Sorensen JA, Cruz M, Avera SP, Numakawa G. Microleakage and marginal fidelity of gold inlays using new cements. *J Dent Res* 1994; 73, 18, Abstr. 136
- Tuntiprawon M, Sermsuti-Anuwat N, Promieng N. Gingival Microleakage of Cast Inlays Luted with Different Cements. *IADR-SEA 1997 (Special Issue)*, Abstract P-53, 104 (Same order as the others; resin the best, then glass ionomer, zinc-oxyphosphate the worst.)
- Lyons KM, Rodda JC, Hood JAA. Use of a Pressure Chamber to Compare Microleakage of Three Luting Agents. *Int J Prosthodont* 1997; 10: 426-433. (Zinc phosphate higher and developed quickest, glass ionomer about 50% of this, but no microleakage with resin (Panavia 21).)
- Michelini FS, Belser UC, Scherrer SS, De Rijk WG. Tensile bond strength of gold and porcelain inlays to extracted teeth using three cements. *Int J Prosthodont* 1995;8:324 331

Dual cure or light cure?

This discussion has been exacerbated by studies showing that an incomplete light cure in advance of the self-cure reduces the conversion rate when compared to self-cure alone. Two trends can be observed:

- cementation with light-curing materials, naturally coupled with long curing times (University of Zuerich and CEREC as a prominent representative of this direction).
- cementation with self-cure cements rather than dual cure cements.

There is no "final answer" to this question. I do cement my veneers with a flowable composite, because light curing is assured and the color stability is better. (Note: it has been recommended by some lecturers to cement with the light-curing base paste of dual cured composite cements due to better color stability of light-curing materials. However, the instable component – the amine – is not in the catalyst syringe but in the base paste! By following this recommendation, you effectively double the concentration of amine.) The use of a solely self-cure cement (Panavia, Multilink, etc.) will have disadvantages at exposed margins. I restrict my use of these products to root canal posts and cementation of metal restorations.

In most clinical situations, I still believe that a dual-cured material is preferable. Naturally, one must not make the mistake of relying on the self-cure, and recommended curing times should not be ignored.

Both of the following studies compared a light-cure cement with a dual-cure cement. Dual-cure showed better marginal adaptation; which was statistically significant in the first study, only a trend in the latter. These are the only two studies where a direct comparison was made (of which I am aware).

- Hannig M, Ratihl B, Schlichting B. Das Randverhalten von „Kulzer“ Kompositeinlays unter simultaner mechanischer und thermischer Belastung. DZZ 1991;46:618-621
- Krejci I, Picco U, Lutz F. Dentinhaftung bei zahnfarbenen adhäsiven MOD-Sofortinlays aus Komposite. Schweiz Monatsschr Zahnmed 1990;100:1151-1159

Silanes

Silane reacts with itself, essentially “deactivating” it over time. There is no visible change in the material. Be sure it is not expired.

Silanized surfaces are very sensitive to dust contamination, it is therefore a good idea to silane all ceramics immediately prior to cementation. A silane applied by the laboratory technician is probably no longer active.

Gary Unterbrink